

Federico Gualini, Sergio Salina, Fabio Rigotti, Cristian Mazzarini, Diego Longhin, Mauro Grigoletto, Anna Trullenque-Eriksson, Luca Sbricoli, Marco Esposito

Subcrestal placement of dental implants with an internal conical connection of 0.5 mm versus 1.5 mm: Outcome of a multicentre randomised controlled trial 1 year after loading

Key words dental implant, subcrestal placement, aesthetics, bone levels

Purpose: To evaluate whether there are some clinical benefits by placing single dental implants either 0.5 or 1.5 mm subcrestally in healed bone crests.

Materials and methods: Sixty partially edentulous patients requiring two single implant-supported crowns had both sites randomly allocated either to 0.5 mm or 1.5 mm subcrestal implant placement according to a split-mouth design at six centres. Implants were submerged in aesthetic areas or non-submerged in non-aesthetic areas for 3 months. Provisional acrylic crowns were delivered and were replaced after 2 months by definitive metal-ceramic crowns. Patients were followed to 1 year after loading. Outcome measures were: crown and implant failures; complications; aesthetics assessed using the pink esthetic score (PES); peri-implant marginal bone level changes; and patient preference, recorded by blinded assessors.

Results: One patient dropped out. One patient lost both implants to infection at impression taking. Three complications affected three patients of the 0.5 mm group and two complications affected two patients of the 1.5 mm subcrestally placed implants. One patient had complications at both implants. There were no statistically significant differences for complications between group (difference of proportion = 0.02; 95% CI -0.06 to 0.09; P (McNemar test) = 1.000). At delivery of definitive crowns, 2 months after loading, the mean aesthetic score was 11.22 ± 1.91 and 11.12 ± 1.59 for the 0.5 and 1.5 mm group, respectively. At 1 year after loading, the mean aesthetic score was 12.09 ± 1.66 and 12.10 ± 1.52 for the 0.5 and 1.5 mm group, respectively. There were no statistically significant differences between the two groups at 2 months (P (paired t test) = 0.626) or at 1 year (P (paired t test) = 0.920). One year after loading, patients of the 0.5 mm lost on average 0.21 ± 0.51 mm and those of the 1.5 mm group 0.11 ± 0.36 mm, the difference being not statistically significant (difference = 0.10; 95% CI -0.01 to 0.20; P (paired t test) = 0.078). Patients did not prefer any depth of the implant placement over the other. There were no differences in outcomes between centres.

Conclusions: No statistical or clinical differences were noticed when placing implants 0.5 mm or 1.5 mm subcrestally, therefore clinicians can do as they prefer.

Conflict-of-interest statement: Anthogyr (Sallanches, France), the manufacturer of the implants used in this investigation, partially funded this trial and donated the implants and the prosthetic components, however data belonged to the authors and by no means did the sponsor interfere with the conduct of the trial or the publication of its results.



Federico Gualini, MD, DDS, MSD
Private practices in Lovere and Bergamo, Italy

Sergio Salina, DDS
Specialist in Oral Surgery, private practice in Milan, Italy

Fabio Rigotti, DDS
Private practice in Verona, Italy

Cristian Mazzarini, DDS
Private practice in Preganziol, Italy

Diego Longhin, DDS
Private practice in Campagna Lupia, Italy

Mauro Grigoletto, DDS
Private practice in Noventa Padovana, Italy

Anna Trullenque-Eriksson, DDS, PhD
Folktandvården Sylte, Trollhättan, Sweden and Honorary Research Fellow in the Institute of Dentistry at the Barts and The London School of Medicine and Dentistry, Queen Mary, London, UK

Luca Sbricoli, DDS, PhD
Department of Neurosciences, University of Padua, Padua, Italy

Marco Esposito, DDS, PhD
Freelance researcher and Associated Professor, Department of Biomaterials, The Sahlgrenska Academy at Göteborg University, Sweden

Correspondence to:
Marco Esposito
Casella Postale 34,
20862 Arcore (MB), Italy
Email:
espositomarco@hotmail.com

■ Introduction

Among the legends circulating in implant dentistry there is the belief that aesthetics can be improved by placing implants in a subcrestal position. The origins of this myth are difficult to trace but some authors attribute this to Buser¹. His original statement referred to ITI transmucosal implants with a polished collar to have the transition portion between the rough section and the polished collar to be placed 1 mm below the bone crest in vertically augmented bone. A dedicated randomised controlled trial (RCT) conducted in non-augmented bone tested this hypothesis². No statistically significant differences were observed in peri-implant marginal bone levels and other secondary parameters 1 year after loading, but the authors concluded anyhow that 'From a biological point of view, the placement of the border between the rough and the smooth surfaces into a subcrestal location should not be recommended'.

More recently, another RCT³ evaluated the influence of the placement level of implants with a laser-microtextured collar design on the outcomes of crestal bone and soft tissue levels in the case of immediate post-extractive implants. Patients were randomly assigned to have the implant placed at the palatal crest or 1 mm subcrestally. Patient were followed up to 12 months post surgery (8 months post-loading). No statistically significant differences were observed at 8 months post-loading. The authors concluded that 'the level of placement did not influence horizontal and vertical bone and soft tissue changes'.

Another RCT⁴ evaluated platform-switched implants with a Morse taper connection, placed at crestal level, 1 and 2 mm subcrestally. One year after loading, there was a statistically significant difference of 0.27 mm more bone loss for implants positioned at crestal level than for those positioned 1 and 2 mm below, but no difference between those placed 1 and 2 mm below the crest. These results were confirmed by another RCT⁵ in which platform-switched implants were placed at crestal level or 1 mm below the crest. Three years after loading, significantly more bone loss (0.65 mm) was observed for crestally placed implants with no difference for all the remaining parameters evaluated. Finally, in a RCT⁶, with a follow-up of only 3 months, using two differ-

ent implant types which were not even loaded, no significant differences in bone levels and other parameters were found for implants placed crestally or 1.5 to 2 mm subcrestally, though no realistic conclusions can be derived from a study in which implants were not even loaded.

Therefore, it would be interesting to know whether we could have a better aesthetic outcome by placing implants 1.5 mm subcrestally or whether similar results can be obtained by placing implants 0.5 mm subcrestally.

The aim of this pragmatic multicentre RCT was to evaluate whether there are some clinical benefits by placing single dental implants either 0.5 or 1.5 mm subcrestally in healed bone crests. This is the first report of a series presenting data at 1 year after loading. At protocol stage, it was planned to follow the patients up to 5 years after loading. The present article is reported according to the CONSORT statement to improve the quality of reports of parallel group randomised trials (<http://www.consort-statement.org/>).

■ Materials and methods

■ Trial design

This was a multicentre RCT of split-mouth design and blind assessment. Each patient received two identical implants (one test and one control implant): the test implant was placed 1.5 mm below the crest and the control implant 0.5 mm subcrestally.

■ Patient selection

Any patient requiring at least two single implant-supported crowns in any jaw location, being at least 18 years old and able to sign an informed consent form was eligible for inclusion. The two implant sites could be adjacent and had to allow the placement of two implants at least 6.5 mm long and 3.4 mm wide leaving at least 1 mm of bone around the implant. For patients with more than two suitable implant sites, the operator chose those two sites with more similar characteristics at the screening visit. The operator coded the selected sites as implant site number 1 and implant site number 2.

Exclusion criteria were:

- general contraindications to implant surgery;
- immunosuppressed or immunocompromised patients;
- irradiation in the head and/or neck area;
- uncontrolled diabetes;
- pregnancy or lactating;
- untreated periodontitis;
- poor oral hygiene and motivation;
- substance abusers;
- psychiatric disorders;
- unrealistic expectations;
- acute infection or suppuration at any of the sites intended for implant placement;
- need of any type of bone augmentation at implant placement;
- post-extractive sites (implants can be inserted after a healing of at least 5 months);
- unable to commit to 5-year follow-up post-loading;
- under treatment or had previous treatment with intravenous amino-bisphosphonates;
- patients referred only for implant placement if the follow-up cannot be done at the treatment centre;
- participation to other clinical studies if the present protocol could not be fully adhered to.

Patients were divided into three groups based on the number of cigarettes they declared to consume per day: i) non-smokers; ii) moderate smokers (up to 10 cigarettes per day); and iii) heavy smokers (more than 10 cigarettes per day).

Equal numbers of patients were recruited and treated by six different doctors – Salina, Gualini, Rigotti, Mazzarini, Longhin and Grigoletto – in private practices located in Northern Italy using similar and standardised procedures. Each clinician treated ten patients. Prior to enrolment, all patients were asked to sign an informed consent form to document that they understood the scope of the study (including procedures, follow-up evaluations, and any potential risks involved), were allowed opportunities to ask questions pertaining to this study, and were apprised of treatment alternatives. The study was open to any qualifying patients without regard to sex or race. All patients received thorough explanations and signed a written informed consent form prior to be enrolled in the trial.

■ Clinical procedures

Preoperative radiographs were taken. Investigators were free to choose the most appropriate examination according to the clinical case between periapical, panoramic and cone beam computed tomography. All patients underwent at least one oral hygiene session within 10 days prior to the implantation procedure.

Patients received a single dose of prophylactic antibiotic 1 hour prior to the intervention: 2g of amoxicillin or 500 mg of clarithromycin, if allergic to penicillin. Patients rinsed with chlorhexidine mouthwash 0.2% for 1 min prior to the intervention. Patients were treated under local anaesthesia using articaine with adrenaline 1:100,000. No intravenous sedation was used. After crestal incision and flap elevation, the sequentially numbered sealed envelope corresponding to the patient recruitment number was opened and implant site number 1 was treated according to the content of the envelope. Consequently, the other intervention was delivered to implant site number 2, according a split-mouth design (Figs 1a–j). The two study implants were placed in the same surgical session following similar procedures and were restored simultaneously with similar single crowns. Bone quality was subjectively quantified at drilling as: 'hard', 'medium' and 'soft'. Implant sites were prepared using drills with increasing diameters as suggested by the implant manufacturer using burs of different lengths according to the random allocation. Tapping was used in hard bone. Tapered implants (Axiom REG, Anthogyr, Sallanches, France) with internal Morse tapered connection and platform switching, made of titanium alloy Ti4V6Al (grade 5), were used. The surface was sandblasted with biphasic calcium phosphate (BCP) bioceramics consisting of a mixture of hydroxyapatite (HA) and β -TCP (beta-tricalcium phosphate), and then subjected to mild acid treatment. Operators were free to use implants of diameters 3.4 mm (8.0, 10.0, 12.0 and 14.0 mm long), 4.0 mm, 4.6 mm and 5.4 mm (6.5, 8.0, 10.0, 12.0 and 14.0 mm long), according to clinical indications and operator preference.

According to the random allocation, the neck of the implant was sunk subcrestally for 0.5 mm or 1.5 mm using the apical peak of the surrounding bone as a reference point. Periapical radiographs

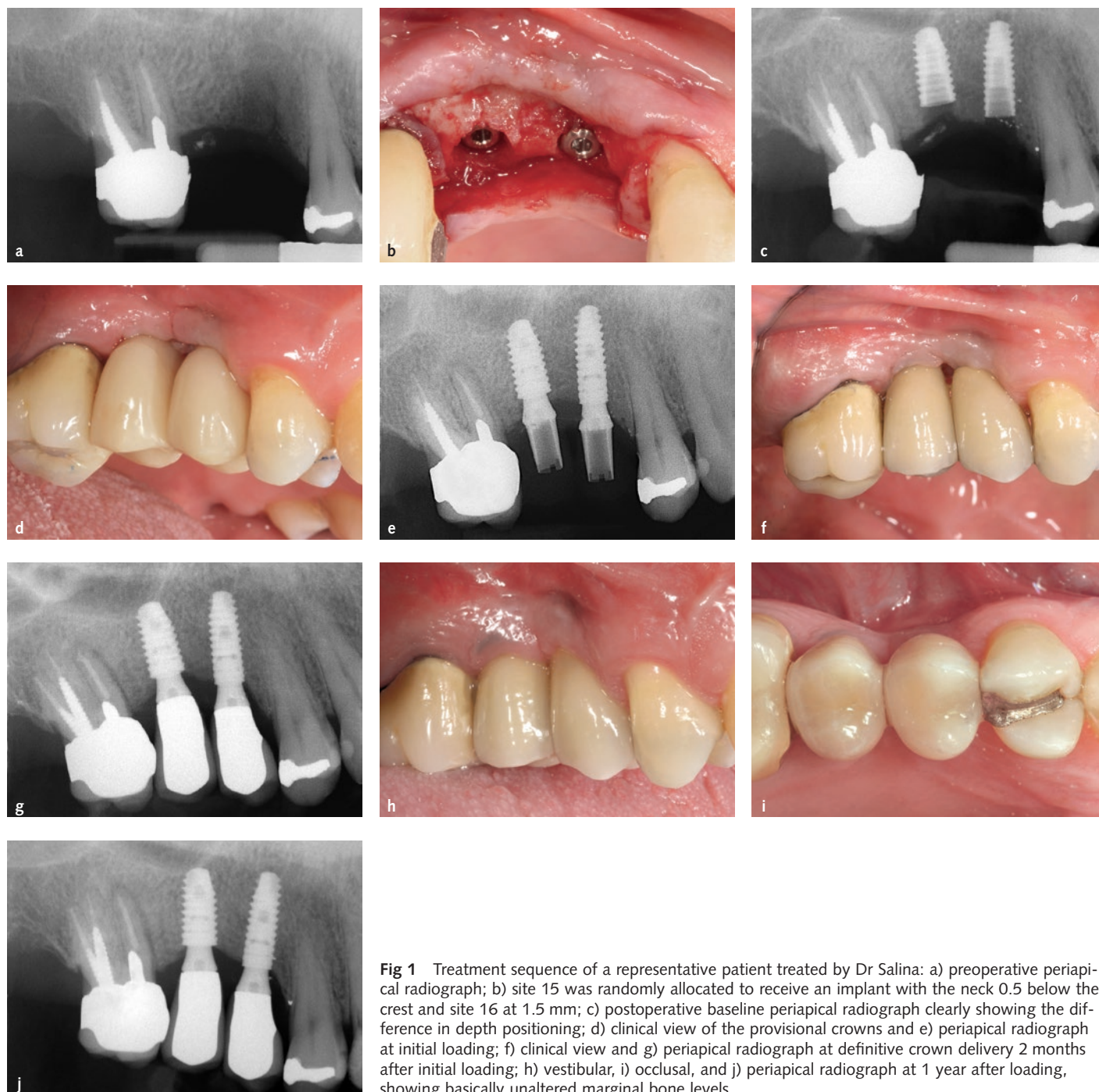


Fig 1 Treatment sequence of a representative patient treated by Dr Salina: a) preoperative periapical radiograph; b) site 15 was randomly allocated to receive an implant with the neck 0.5 below the crest and site 16 at 1.5 mm; c) postoperative baseline periapical radiograph clearly showing the difference in depth positioning; d) clinical view of the provisional crowns and e) periapical radiograph at initial loading; f) clinical view and g) periapical radiograph at definitive crown delivery 2 months after initial loading; h) vestibular, i) occlusal, and j) periapical radiograph at 1 year after loading, showing basically unaltered marginal bone levels.

were taken and if the peri-implant marginal bone levels were difficult to evaluate, they were taken again. Implants in aesthetic areas were submerged and implants in non-aesthetic areas received transmucosal healing abutments. Ibuprofen 400 mg was prescribed to be taken 2 to 4 times a day during meals, for as long as required. In case of stomach problems or allergy to non-steroidal anti-inflammatory drugs, 1 g of paracetamol was recommended instead.

Patients were instructed to use 0.2% chlorhexidine mouthwash for 1 min twice a day for 2 weeks, and to avoid brushing and possible trauma on the surgical sites. A soft diet was recommended for 2 weeks. After 1 week, patients were checked and sutures were removed. Implants were left to heal unloaded for 3 months, then submerged implants were exposed and the stability of individual implants was assessed by torquing the abutment screws at 25 Ncm. Impres-

sions were taken at implant level, provisional crowns were delivered on provisional titanium abutments, periapical radiographs were taken, and oral hygiene instructions were delivered. The same procedures were implemented for both implants.

After 2 months, the following definitive standard straight titanium abutments lengths were used: 1.5, 2.5, 3.5 and 4.5 mm. The abutment shoulder was selected to be 0.5 to 1 mm shorter than the buccal gingival margin. The diameters of healing caps and definitive abutments used were 5 mm for implants replacing molars and 3.4 or 4.0 mm for implants replacing other teeth as per clinician evaluation. The provisional restorations were replaced by cemented metal-ceramic definitive crowns provisionally cemented on definitive standard straight titanium abutments. Implant stability was assessed and vestibular and occlusal pictures of the study implants, including one adjacent tooth per side, were taken together with standardised periapical radiographs using an individual stent, and oral hygiene motivation was reinforced. Patients were recalled every 6 months for maintenance for the entire duration of the study. Dental occlusion was evaluated at each visit.

■ Outcome measures

This study tested the null hypothesis that there were no differences in clinical outcome between the two procedures against the alternative hypothesis of a difference.

Outcome measures were:

- Implant/crown failures: implant mobility, removal of stable implants dictated by progressive marginal bone loss or infection, and any mechanical complications rendering the implant not usable (e.g. implant fracture) were considered implant failures. If a definitive crown had to be replaced for any reason, it counted as a crown failure. The stability of individual implants was measured at delivery of definitive crowns, 2 months after implant placement, applying a reverse torque of 20 Ncm with a dedicated wrench. Implant stability was reassessed at 1 year after loading using the metal handles of two instruments.
- Any biological or biomechanical complications. Examples of biological complications are fistula and peri-implantitis. Examples of biomechanical complications are loosening or fracture of the abutment screws.
- Peri-implant marginal bone level changes evaluated on periapical radiographs taken with the paralleling technique at implant placement, initial loading and 1 year after loading. In the case of a non-measurable radiograph, a second radiograph was taken. Radiographs were scanned into TIFF format with a 600 dpi resolution, and stored in a personal computer. Peri-implant marginal bone levels were measured using the ImageJ software, version 1.48 (NIH, Bethesda, MD, USA). The software was calibrated for every single image using the known distance of the two more coronal consecutive threads and/or the implant diameter. Measurements of the mesial and distal bone crest level adjacent to each implant were made to the nearest 0.01 mm. Reference points for the linear measurements were the coronal margin of the implant collar and the most coronal point of visible bone-to-implant contact. The measurements at mesial and distal sides of each implants were averaged at implant level and then at group level. All radiographic measurements were made by a blinded dentist (Dr Sbricoli).
- Aesthetic evaluation of the vestibular and occlusal clinical pictures, including the two adjacent teeth, taken at delivery of the definitive crowns (2 months after initial loading) and 1 year after loading was performed on a computer screen by a blinded dentist (Dr Sbricoli). The aesthetic evaluation was done using the pink esthetic score (PES)⁷. In brief, seven variables were evaluated: mesial papilla, distal papilla, soft tissue level, soft tissue contour, alveolar process deficiencies, soft tissue colour and texture. A 0-1-2 scoring system was used, 0 being the lowest and 2 being the highest value, with a maximum achievable score of 14 per implant.
- Patient preference. One year after loading the local blind outcome assessors provided a mirror to patients, indicated both implant-supported crowns and asked them which of the crowns they preferred. Possible patient's answers were: i) crown in implant site number 1; ii) crown in implant site number 2; iii) I like both crowns the same; iv) I dislike both crowns. Patients could express comments on the matter if they wanted.

At each centre, there was a local blind outcome assessor who assessed implant stability and recorded patient preference. One blinded dentist (Dr Sbricoli), not involved in the treatment of the patients, evaluated both aesthetic and marginal bone levels, without knowing group allocation, therefore outcome assessment was performed blindly with the exception of complications which were handled and reported directly by the responsible clinicians who were not blind.

■ Statistical analysis

No sample size calculation was performed and it was agreed to recruit 60 patients, 10 at each of the six centres that agreed to participate in this trial. Six computer-generated restricted randomisation lists were created. Only one investigator (Dr Esposito), who was not involved in the selection and treatment of the patients, knew the random sequence and had access to the random list stored in a password-protected portable computer. The randomised codes were enclosed in sequentially numbered, identical, opaque, sealed envelopes. After flap elevation, the envelope corresponding to the patient recruitment number was opened, and implant site number 1 was allocated to the group determined by the content of the envelope, and other sites received the alternative intervention. Therefore, treatment allocations were concealed to the investigators in charge of enrolling and treating the patients.

All data analysis was performed according to a pre-established analysis plan by a dentist (Dr Trullenque-Eriksson) with expertise in statistics who analysed the data without knowledge of the group codes. The patient was the statistical unit of the analyses. Differences in the proportion for dichotomous outcomes (crown/implant failures and complications) were compared between the groups using a McNemar chi-square test. Differences between the groups for continuous outcomes (mean marginal bone level changes and aesthetics assessed by dentist) were compared using a paired *t* test. Comparisons between the various follow-up endpoints and the baseline measurements were made by paired *t* tests, to detect any changes in mean marginal bone level changes for each study group. Differences between centres for continuous

outcomes were analysed by the analysis of variance (ANOVA) test, followed by Tukey's honest significant difference (HSD) post hoc test to detect differences between groups. For categorical outcomes, the chi-square test was used. All statistical comparisons were conducted at the 0.05 level of significance.

■ Results

Sixty-three patients were screened at the six centres and 60 patients were consecutively enrolled in the trial. Three patients were not included because they did not want to participate in the study. All patients were treated according to the allocated interventions. One patient dropped out because he did not want to come back after the delivery of the provisional crowns (Dr Longhin).

The periapical radiographs at 2 months and 1 year after loading of both implants of one patient could not be taken because she was pregnant at both timepoints (Dr Rigotti). The data of all remaining patients were evaluated in the statistical analyses. The main deviations from the protocol were:

- In one patient, both definitive crowns were placed 11 months after loading, because the patient had health problems and did not plan to return (Dr Salina).
- In one patient both definitive crowns were placed 9 months after the provisional. The definitive crown delivery, 9 months after loading, was considered as the 1-year post-loading visit (Dr Rigotti).
- In one patient, only for the implant placed 1.5 mm below the crest, a straight abutment was used instead of standard abutment (Dr Salina).

Patients were recruited and received the implants from June 2013 to April 2015. The follow-up of all remaining patients was to 1 year after implant loading. There were 34 females and 26 males, with a mean age of 53.4 years (range 28 to 81). There were 47 non-smokers, six moderate smokers and seven patients smoking more than 10 cigarettes per day. Implant characteristics by study groups are described in Table 1. There were no apparent significant baseline imbalances between the two groups.

- Crowns and implant failures: two implants failed, one per group, from the same patient. The differences in proportions of implant failures between groups was not statistically significant (difference of proportion = 0; 95% CI -0.05 to 0.05; *P* (McNemar test) = 1.000). Both implants, which were initially loaded with provisional crowns, showed a fistula and were found mobile at definitive impression taking and so were removed. Both failed implants were successfully replaced but the data of the replaced implants were not recorded since they fell outside the scope of the present study.
- Complications: three complications occurred in three patients of the 0.5 mm group versus two complications in two patients of the 1.5 mm group. One patient had both implants affected by the same complication (fistula/infection). There was no statistically significant difference in number of patients experiencing complications between the two groups (difference of proportion = 0.02; 95% CI -0.06 to 0.09; *P* (McNemar test) = 1.000). At the 0.5 mm group, one patient had an episode of peri-implant mucositis at implant in position 27 (pocket depth palatally = 4.5 mm). The patient was immediately treated with light ultrasonic treatment using polytetrafluoroethylene (PTFE) tips and one application of 810 nm diode laser (1.2 watts for 1 min × 3 times) with simultaneous irrigation of 3% H₂O₂. The peri-implant sulcus was then filled with a gel of chlorhexidine 0.5% (Oralsan, IDS, Genova, Italy) and azithromycin (Zitromax, Pfizer, Latina, Italy) 500 mg (one tablet per day for 3 days) was prescribed. The situation returned to normality in 20 days. The patient was recalled monthly for 6 months. Another patient presented an inflammatory problem at time of abutment connection around the implant in position of 46, which resulted in bone loss at 1 year after loading (peri-implantitis). She was treated by light scaling with a polytetrafluoroethylene (PTFE) tip using the piezoelectric device (Mectron, Carasco, Italy) and curettes, irrigation of physiologic saline and injection of a solution of tetracycline hydrochloride (Ambramicina, 250 mg, Scharper, Milan, Italy). This treatment was repeated after 2 weeks. Another patient presented a fistula and implant in position 14, which was mobile at the time of definitive impression taking. It was removed and suc-

Table 1 Intervention characteristics

	0.5 mm N = 60	1.5 mm N = 60
Implants in central incisor position	0	0
Implants in lateral incisor position	0	0
Implants in canine position	1 (1.7%)	0
Implants in first premolar position	7 (11.7%)	9 (15%)
Implants in second premolar position	15 (25%)	16 (26.7%)
Implants in first molar position	31 (51.7%)	30 (50%)
Implants in second molar position	5 (8.3%)	5 (8.3%)
Implants in third molar position	1 (1.7%)	0
Implants in maxillae	17 (28.3%)	15 (25%)
Implants in mandibles	43 (71.7%)	45 (75%)
Implants with 3.4 mm diameter	21 (35%)	21 (35%)
Implants with 4.0 mm diameter	35 (58.3%)	35 (58.3%)
Implants with 4.6 mm diameter	2 (3.3%)	3 (5%)
Implants with 5.2 mm diameter	2 (3.3%)	1 (1.7%)
Implants 6.5 mm long	6 (10%)	8 (13.3%)
Implants 8.0 mm long	24 (40%)	30 (50%)
Implants 10.0 mm long	28 (46.7%)	22 (36.7%)
Implants 12.0 mm long	2 (3.3%)	0
Implants 14.0 mm long	0	0
Abutment 1.5 mm long	33 (55%)	19 (31.7%)
Abutment 2.5 mm long	20 (33.3%)	31 (51.7%)
Abutment 3.5 mm long	7 (11.7%)	10 (16.7%)
Abutment 4.5 mm long	0	0
Abutment 3.4 mm in diameter	4 (6.7%)	1 (1.7%)
Abutment 4.0 mm in diameter	31 (51.7%)	37 (61.7%)
Abutment 5.0 mm in diameter	23 (38.3%)	21 (35%)
Abutment 6.0 mm in diameter	2 (3.3%)	1 (1.7%)
Soft bone quality	8 (13.3%)	6 (13.3%)
Medium bone quality	31 (51.7%)	34 (56.7%)
Hard bone quality	21 (35%)	20 (33.3%)

cessfully replaced. The complications reported for patients of the 1.5 mm group were: a fistula at the implant in position 15 mobile in the same patient that lost this and the adjacent implant. Another patient lost the cover screw on tooth 36 one week after its placement; the soft tissues covered the implant and no treatment was necessary.

- Aesthetics: two months after loading, at delivery of the definitive prostheses, the average total PES score, assessed by a blind assessor, was 11.22 ± 1.91 for the 0.5 mm group and 11.12 ± 1.59 for the 1.5 mm group, the difference being not statistically significantly different

Table 2a Pink esthetic scores (PES) at 2 months after loading by groups and by different aesthetic domains (standard deviations [SDs] in parentheses)

	Mesial papilla	Distal papilla	Soft tissue level	Soft tissue contour	Alveolar process deficiencies	Soft tissue colour	Soft tissue texture	Total PES score
0.5 mm deep N = 58	1.40 (0.70)	1.00 (0.77)	1.84 (0.37)	1.57 (0.53)	1.81 (0.40)	1.81 (0.40)	1.79 (0.41)	11.22 (1.91)
1.5 mm deep N = 58	1.40 (0.67)	0.97 (0.67)	1.86 (0.35)	1.52 (0.57)	1.81 (0.40)	1.79 (0.41)	1.78 (0.42)	11.12 (1.59)
Difference [95% CI]	0.00 [-0.25, 0.25]	0.03 [-0.16, 0.23]	-0.02 [-0.14, 0.11]	0.05 [-0.06, 0.17]	0.00 [-0.07, 0.07]	0.02 [-0.08, 0.11]	0.02 [-0.09, 0.12]	0.10 [-0.32, 0.53]
<i>P</i> value (paired <i>t</i> test)	1.000	0.727	0.784	0.370	1.000	0.709	0.742	0.626

Table 2b PES scores at 1 year after loading by groups and by different aesthetic domains (SD in parenthesis)

	Mesial papilla	Distal papilla	Soft tissue level	Soft tissue contour	Alveolar process deficiencies	Soft tissue colour	Soft tissue texture	Total PES score
0.5 mm deep N = 58	1.71 (0.50)	1.33 (0.69)	1.86 (0.35)	1.69 (0.50)	1.81 (0.40)	1.83 (0.38)	1.86 (0.35)	12.09 (1.66)
1.5 mm deep N = 58	1.67 (0.57)	1.33 (0.57)	1.90 (0.31)	1.74 (0.48)	1.81 (0.40)	1.83 (0.38)	1.83 (0.38)	12.10 (1.52)
Difference [95% CI]	0.03 [-0.16, 0.23]	0.00 [-0.19, 0.19]	-0.03 [-0.14, 0.08]	-0.05 [-0.17, 0.06]	0.00 [-0.10, 0.10]	0.00 [-0.10, 0.10]	0.03 [-0.06, 0.13]	-0.02 [-0.36, 0.33]
<i>P</i> value (paired <i>t</i> test)	0.718	1.000	0.532	0.370	1.000	1.000	0.484	0.920

(*P* (paired *t* test) = 0.626; Table 2a). Also, when evaluating the individual aesthetic domains, no statistically significant difference could be observed between the two groups (Table 2a). One year after loading, the average PES score was 12.09 ± 1.66 for the 0.5 mm group and 12.10 ± 1.52 for the 1.5 mm group, the difference being not statistically significantly different (*P* (paired *t* test) = 0.920; Table 2b). In addition, when evaluating the individual aesthetic domains, no statistically significant difference could be observed between the two groups (Table 2a).

- Patient preference was assessed at definitive crown delivery, 2 months after initial loading, and at 1 year after initial loading only for those patients who did not experience an implant failure. At delivery of definitive crowns, 57 patients had no preferences (liking both crowns the same way) and one patient preferred the 1.5 mm crown. At 1 year after loading, 55 patients had no preference (liking both crowns the same way), two patients preferred the 0.5 mm one, and another the 1.5 mm one.

- Peri-implant marginal bone levels were evaluated by a blinded outcome assessor on periapical radiographs taken at implant placement, at loading, and at 1 year after loading (Table 3a). At baseline, all bone level measures equalled 0 for both groups. At initial loading, the average bone levels around 0.5 mm implants were 0.07 ± 0.21 mm versus 0.04 ± 0.13 mm at 1.5 mm implants, the difference being not statistically different (difference = 0.03; 95% CI -0.02 to 0.07; *P* (paired *t* test) = 0.209). At 1 year post-loading, the average bone levels around 0.5 mm implants were 0.21 ± 0.51 mm versus 0.11 ± 0.36 mm at 1.5 mm implants, the difference being not statistically different (difference = 0.10; 95% CI -0.01 to 0.20; *P* (paired *t* test) = 0.078). Bone level loss at 1 year post-loading were 0.21 ± 0.51 mm at 0.5 mm implants and 0.11 ± 0.36 mm at 1.5 mm implants, but the difference was not statistically significant (difference = 0.10; 95% CI -0.01 to 0.20; *P* (paired *t* test) = 0.078; Table 3b).

The comparison between the six centres is presented in Table 4. At 1 year post-loading, there

Table 3a Mean radiographic peri-implant marginal bone levels between groups and time periods up to 1 year after loading

	Implant placement	Loading	2 months post-loading	1 year post-loading
	N Mean (SD) [95% CI]	N Mean (SD) [95% CI]	N Mean (SD) [95% CI]	N Mean (SD) 95% CI
0.5 mm deep	59 All implants = 0	59 0.07 (0.21) [0.01, 0.12]	57 0.16 (0.39) [0.06, 0.26]	57 0.21 (0.51) [0.07, 0.34]
1.5 mm deep	59 All implants = 0	59 0.04 (0.13) [0.01, 0.07]	57 0.10 (0.38) [-0.01, 0.20]	57 0.11 (0.36) [0.02, 0.21]
Difference [95% CI]	0	0.03 [-0.02, 0.07]	0.06 [-0.02, 0.15]	0.10 [-0.01, 0.20]
P value	1.000	0.209	0.152	0.078

Table 3b Mean radiographic peri-implant marginal bone level changes between groups and time periods up to 1 year after loading

	Baseline: loading	Baseline: 2 months post-loading	Baseline: 1 year post-loading
	N Mean (SD) [95% CI]	N Mean (SD) [95% CI]	N Mean (SD) 95% CI
0.5 mm deep	59 0.07 (0.21) [0.01, 0.12]	57 0.16 (0.39) [0.06, 0.26]	57 0.21 (0.51) [0.07, 0.35]
1.5 mm deep	59 0.04 (0.13) [0.01, 0.07]	57 0.10 (0.38) [-0.01, 0.20]	57 0.11 (0.36) [0.02, 0.21]
Difference [95% CI]	0.03 [-0.02, 0.07]	0.06 [-0.02, 0.15]	0.10 [-0.01, 0.20]
P value	0.209	0.152	0.078

All changes from baseline statistically different ($P < 0.05$).

Table 4 Comparison of clinical outcomes between the six centres at 1 year after loading

	Salina	Gualini	Rigotti	Mazzarini	Longhin	Grigoletto	P value
Drop-out	0/10	0/10	0/10	0/10	1/10	0/10	0.406
Crown failures	0/10	0/10	0/10	1*/10	0/9	0/10	0.418
Implant failures	0/10	0/10	0/10	1*/10	0/9	0/10	0.418
Complications	1/10	0/10	2/10	1*/10	0/9	0/10	0.392
PES score 1 year 0.5 mm group	11.80 ± 1.99	12.40 ± 1.27	12.80 ± 1.03	12.44 ± 1.13	12.00 ± 1.66	11.10 ± 2.28	0.263
PES score 1 year 1.5 mm group	12.50 ± 0.97	12.30 ± 1.25	12.40 ± 1.17	12.22 ± 1.20	12.11 ± 1.90	11.10 ± 2.18	0.348
Peri-implant bone loss 1 year 0.5 mm group	0.44 ± 0.90	0.12 ± 0.38	0.36 ± 0.69	0.08 ± 0.16	0.19 ± 0.30	0.07 ± 0.15	0.506
Peri-implant bone loss 1 year 1.5 mm group	0.37 ± 0.70	0.04 ± 0.13	0.18 ± 0.41	0.00 ± 0.00	0.08 ± 0.17	0.00 ± 0.00	0.153
Patients with no preference	9/10	10/10	10/10	8/9	9/9	9/10	0.672

*Both implants of the same patient were affected by complications and then failed.

were no statistically significant differences between the centres for crown and implant failures (P (chi-square test) = 0.418), complications (P (chi-square test) = 0.392), PES score (for the 0.5 mm group, P (ANOVA) = 0.263; for the 1.5 mm group P (ANOVA) = 0.348), peri-implant bone level changes (for the 0.5 mm group, P (ANOVA) = 0.506; for the 1.5 mm group P (ANOVA) = 0.153) and patient preference (P (chi-square test) = 0.672) (Table 4).

Discussion

This trial was designed to evaluate whether it could be more advantageous to place implants 0.5 mm

or 1.5 mm subcrestally. No statistically significant differences were noticed for any of the parameters considered, suggesting that it is clinically irrelevant to sink dental implants subcrestally at least at the depths evaluated in the present trial; therefore, clinicians could choose to place implants at the depths (0.5 or 1.5 mm) they prefer. One purely logical consideration ought to be made: it might be sensible to place implants at a depth of 0.5 mm in order to be able to fully use 1 mm more of bone support, especially for those situations of limited bone heights. Ideally, in the same trial, we should have also tested the placement of the same implants at crestal level or even slightly supracrestally to have a complete vision about the relationships between implant positioning

depth and aesthetic outcome, as well other clinically relevant parameters.

The present findings are in agreement with those of other similar RCTs²⁻⁴ testing the same hypothesis, even though implants with different designs were used, such as transmucosal implants². However, when implants were crestally placed, some statistically significant difference for bone loss were reported. For instance, one RCT⁴ that evaluated platform-switched implants with a Morse taper connection, placed at crestal level, 1 and 2 mm subcrestally, reported 0.27 mm more bone loss for implants positioned at the crestal level 1 year after loading. Another RCT⁵ comparing platform-switched implants at crestal level or 1 mm below showed 0.65 mm more bone loss at crestally placed implants 3 years after loading. However, there is no evidence that such small differences in bone loss affected aesthetics or any other clinical parameter. In simple words, the subcrestal positioning of implants 0.5 or 1.5 mm in healed sites bears no clinically appreciable consequences for the patients.

In the present trial, no statistically significant differences nor trends were observed for aesthetics evaluated using the PES scores, either at 2 months or 1 year after loading between implants positioned 0.5 or 1.5 mm subcrestally. This could be interpreted as both procedures achieved a similar aesthetic outcome. It is interesting to observe that aesthetics slightly improved between month 2 and month 12 post-loading, especially for mesial and distal papillas, suggesting that some sort of creeping attachment phenomena occurred after the delivery of the definitive crowns, meaning that the peri-implant soft tissues gradually grew around the crowns.

Regarding peri-implant marginal bone loss, no statistically significant differences were observed between the two groups for any time intervals up to 1 year after loading, suggesting that the positioning of implants 0.5 or 1.5 mm below the crest bear no clinical impact of the peri-implant marginal bone loss.

While comparing clinical outcomes among different centres, there were no statistically significant differences for implant failures, complications, and peri-implant marginal bone level changes, although the sample was too small to detect possible differences between operators.

Since in the present investigation both procedures were tested in real clinical conditions and patient inclusion criteria were broad, results can be generalised with confidence to a wider population with similar characteristics.

■ Conclusions

No statistical or clinical differences were noticed when placing implant 0.5 mm or 1.5 mm subcrestally, therefore clinicians can do as they prefer.

■ Acknowledgements

We wish to thank the following local outcome assessors for their help with this study: Dr Roberto Ringoli, Dr Piero Gualini, Dr Mandy Pen Shui, Dr Martina Furlanetto, Dr Celon and Dr Giulia Piccirilli.

■ References

1. Buser D, Dula K, Belser U, Hirt H-P, Berthold H. Localized ridge augmentation using guided bone regeneration. I. Surgical procedure in the maxilla. *Int J Periodontics Restorative Dent* 1993;13:29–45.
2. Hämmerle CHF, Brägger U, Bürgin W, Lang NP. The effect of subcrestal placement of the polished surface of ITI implants on marginal soft and hard tissues. *Clin Oral Implants Res* 1996;7:111–119.
3. Koh RU, Oh TJ, Rudek I, Neiva GF, Misch CE, Rothman ED, Wang HL. Hard and soft tissue changes after crestal and subcrestal immediate implant placement. *J Periodontol* 2011;82:1112–1120.
4. Koutouzis T, Neiva R, Nonhoff J, Lundgren T. Placement of implants with platform-switched Morse taper connections with the implant-abutment interface at different levels in relation to the alveolar crest: a short-term (1-year) randomized prospective controlled clinical trial. *Int J Oral Maxillofac Implants* 2013;28:1553–1563.
5. Kutan E, Bolukbasi N, Yildirim-Ondur E, Ozdemir T. Clinical and radiographic evaluation of marginal bone changes around platform-switching implants placed in crestal or subcrestal positions: A randomized controlled clinical trial. *Clin Implant Dent Relat Res* 2015;17(Suppl 2):e364–375.
6. Palaska I, Tsaousoglou P, Vouros I, Konstantinidis A, Menexes G. Influence of placement depth and abutment connection pattern on bone remodeling around 1-stage implants: a prospective randomized controlled clinical trial. *Clin Oral Implants Res* 2016;27:e47–56.
7. Fürhauser R, Florescu D, Benesch T, Haas R, Mailath G, Watzek G. Evaluation of soft tissue around single-tooth implant crowns: the pink esthetic score. *Clin Oral Implants Res* 2005;16:639–644.